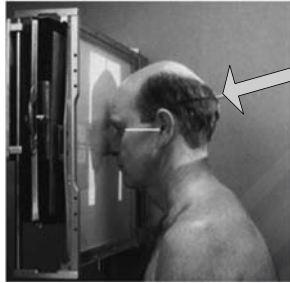


## Extraoral projections



Imad Brinjikji

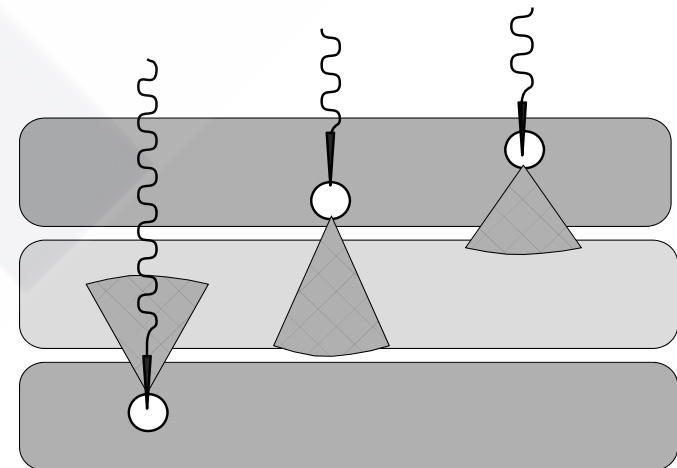
Lecture 3

- In extraoral projections, the X-ray source, the receptors and the patient remain static.
- However, in some digital devices, the receptors and/or the source move during the exposure.
- This is the result of using digital detectors with small-area to reduce the cost of the device.
- Film with intensifying screens may also be used in this technique.

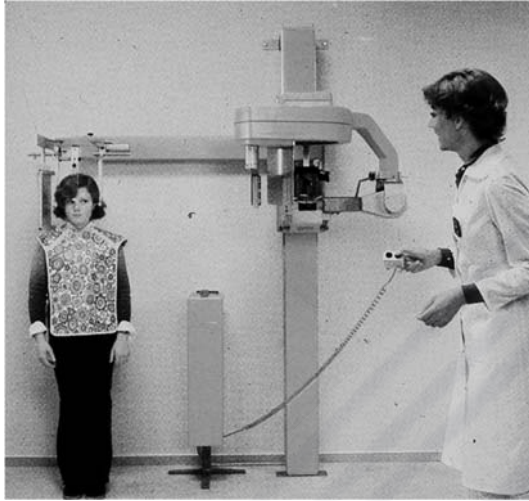
## Cassette/Film



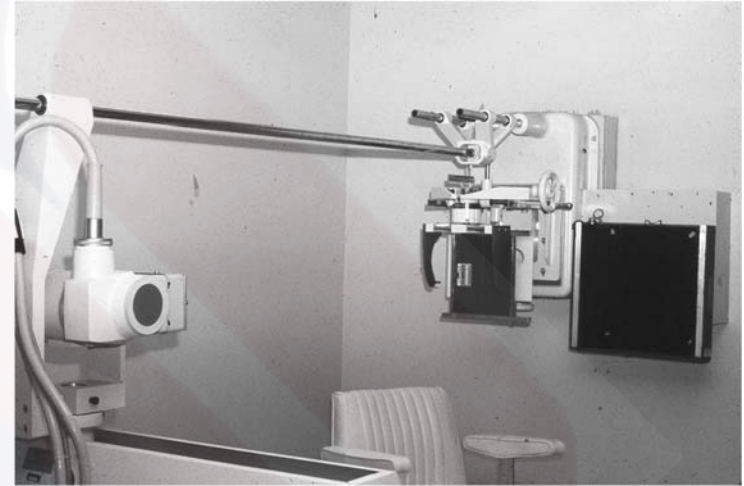
Rare earth elements



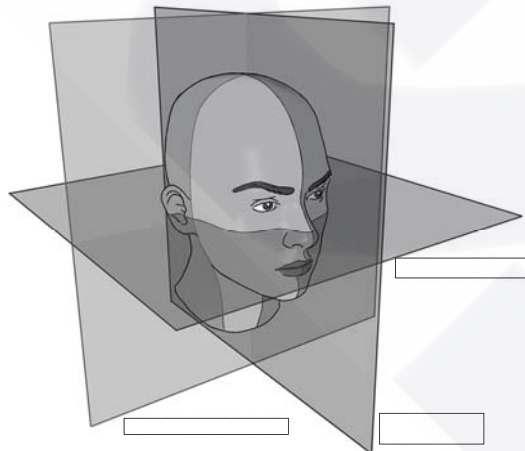
## Panoramic / Cephalometric device



## Specialty Extraoral device

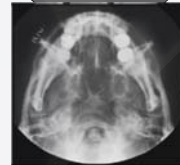


## Extraoral projections

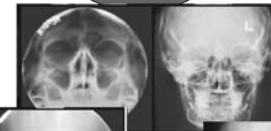

## Extraoral projections

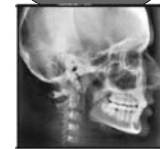Transverse  
(Horizontal)



Coronal  
(Frontal)



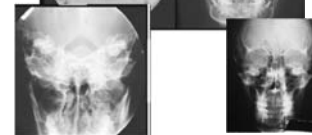Sagittal  
(Median)



Non-orthogonal  
planes

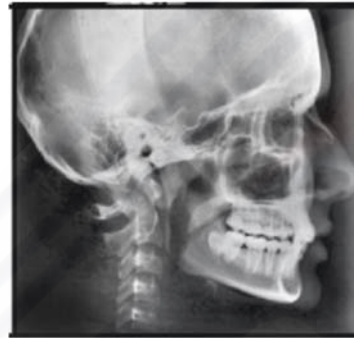TMJ projections

Oblique  
mandibular  
projections



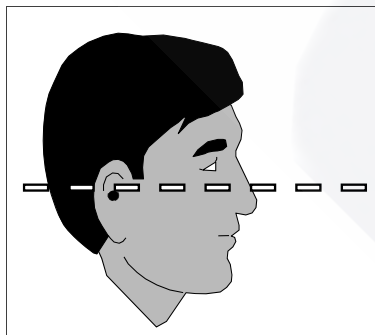
## The main use of extraoral projections

- Evaluation of cranium, face, or cervical spine for diseases, **trauma**, or abnormalities.
- Lateral cephalometric radiograph is used for evaluating growth and development of the face, or treatment progression.



Canthomeatal line is important in extraoral projections.

- This line extends from the central point of the external auditory canal to the outer canthus of the eye.
- This line forms approximately  $10^\circ$  with Frankfort plane (which extends from the superior border of the external auditory canal with the infraorbital rim).
- Usually we change head position in the different projections. Receptors and X-ray source remain static.



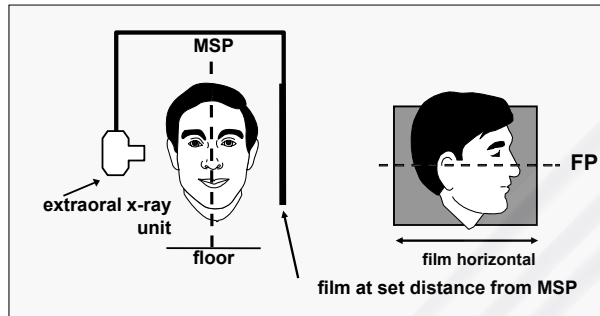
Frankfort plane



Canthomeatal line

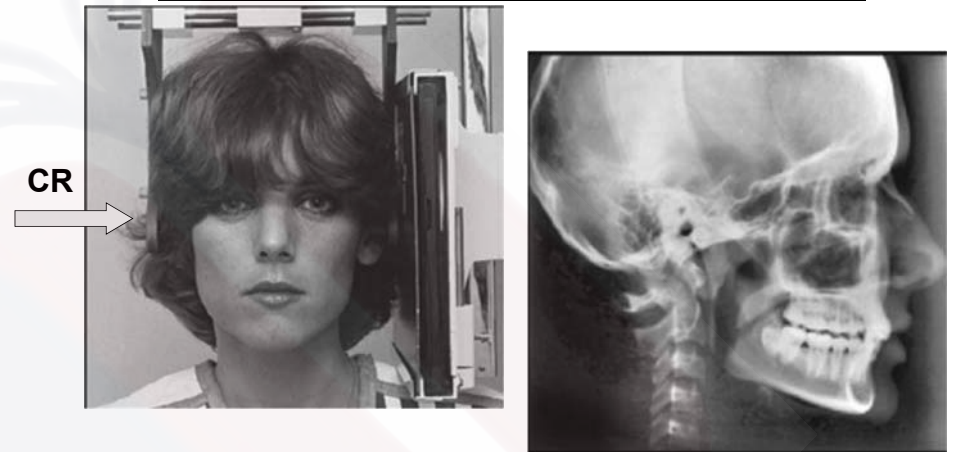**Sagittal (Median) plane**

## Lateral Cephalometric

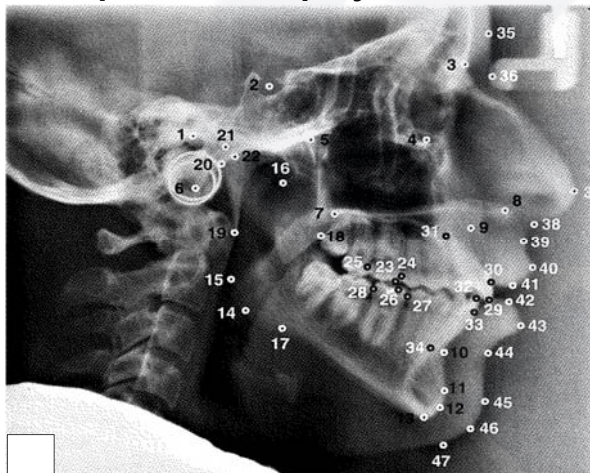


- Film is parallel to midsagittal plane.
- Central ray (CR) is centered over the external auditory meatus.

## Lateral Cephalometric



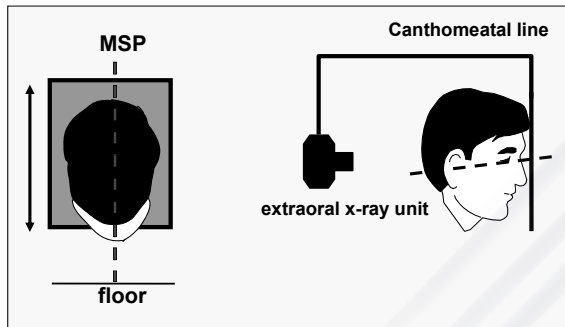
### The lateral cephalometric projection



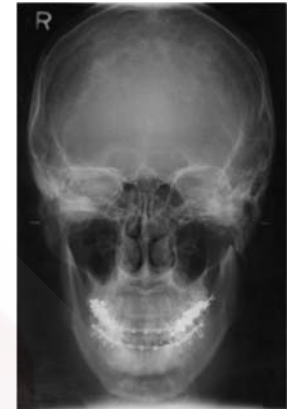### Coronal (Frontal) plane



## I. Posteroanterior (PA) Skull

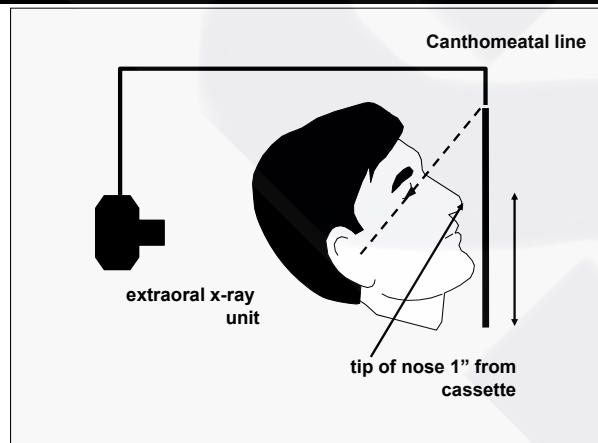


10°

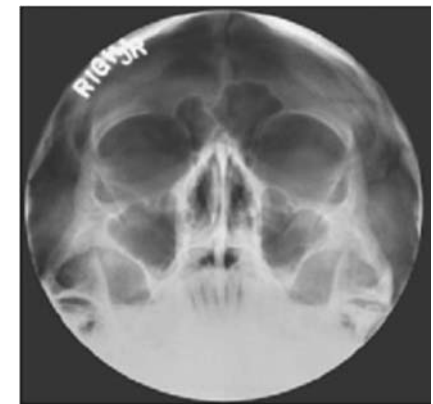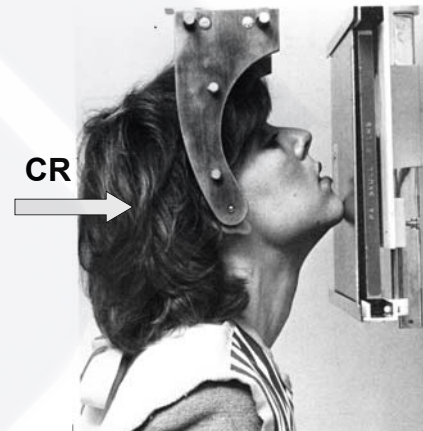


## I. Posteroanterior (PA) Skull

## II. Waters

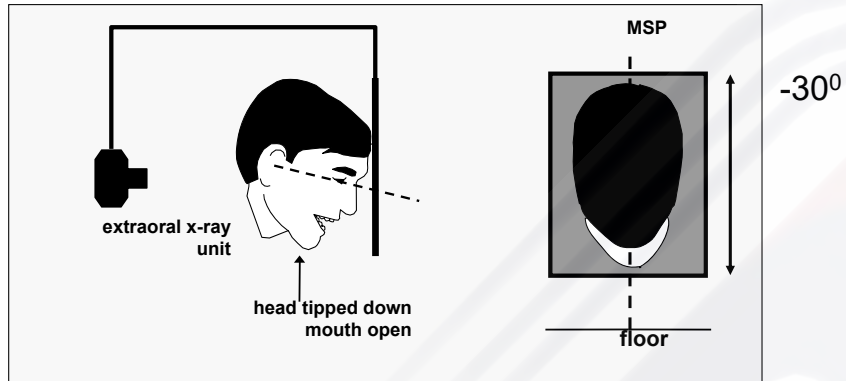


37°

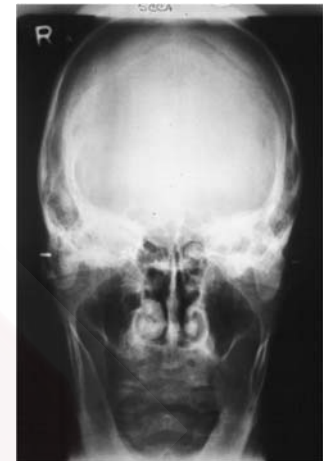


## II. Waters

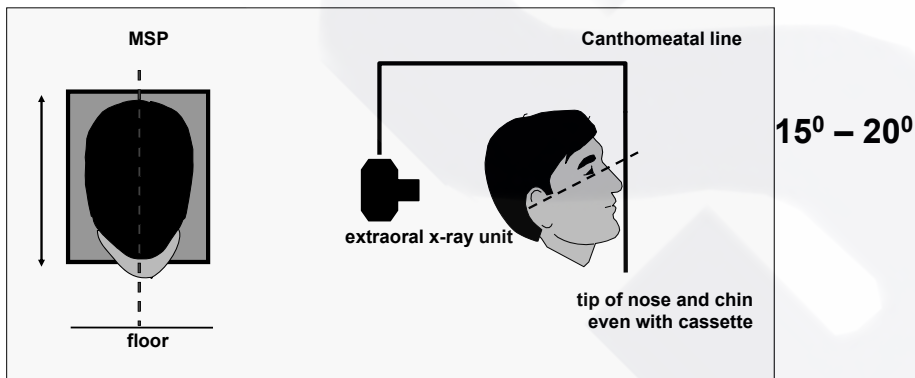
### III. Reverse Townes



### III. Reverse Townes

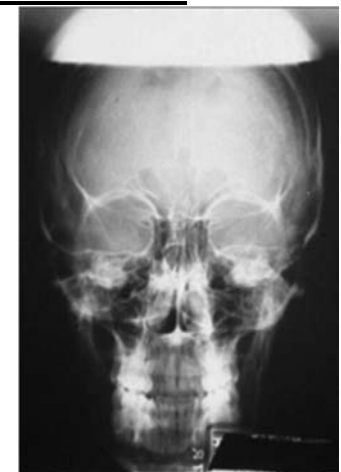

### IV. Caldwell



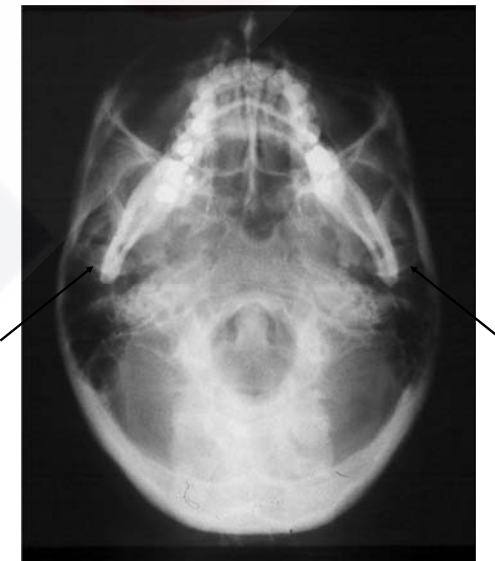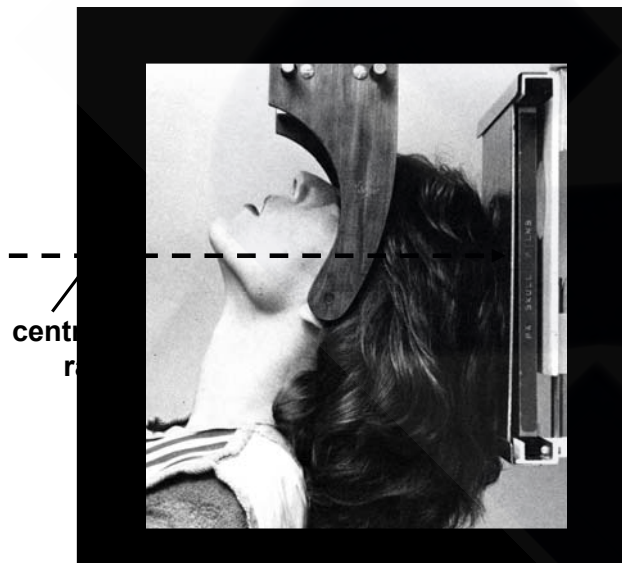
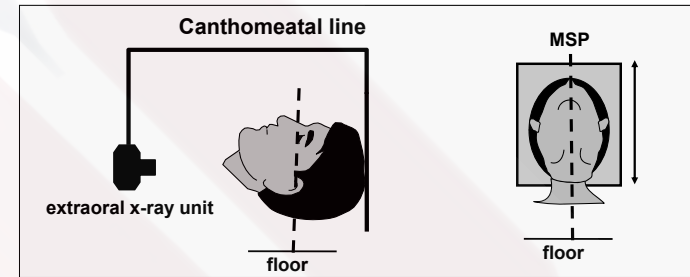
### IV. Caldwell

CR →

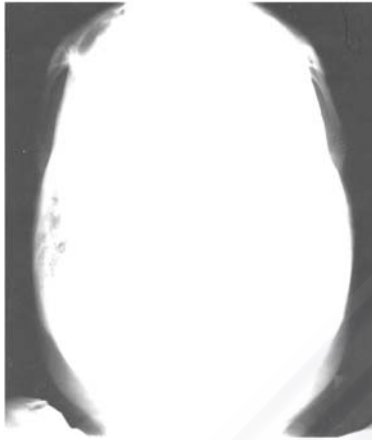


## Submentoverte

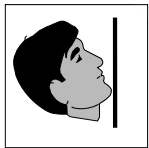
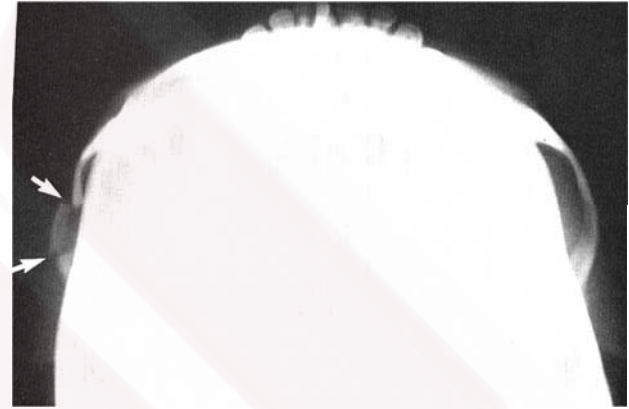
### Transverse (Horizontal) plane



## Zygomatic Arch View



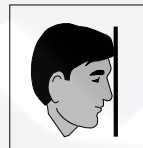Reduce exposure by one-third



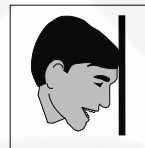
Water's




Caldwell



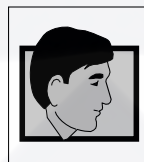
PA



Reverse  
Townes



Submentovertex



Lateral Ceph

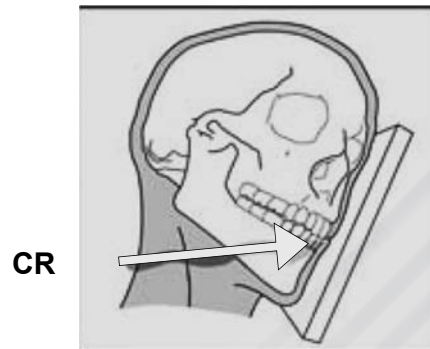# Mandibular oblique lateral projections



## Mandibular oblique body projection

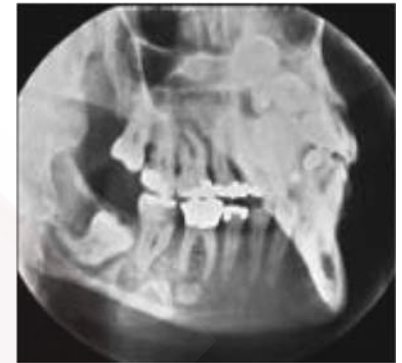---

The beam is directed a the premolar-molar area.



## Mandibular oblique body projection

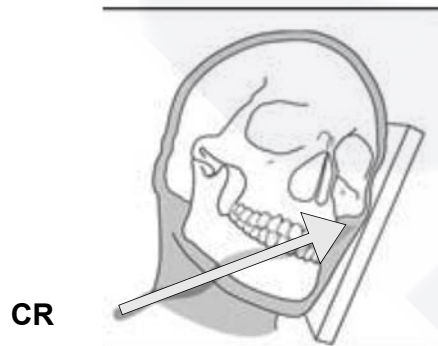
---



## Mandibular oblique ramus projection

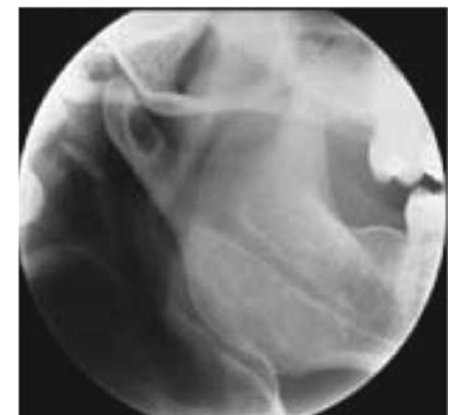---

The beam is directed a the ramus area.



## Mandibular oblique ramus projection

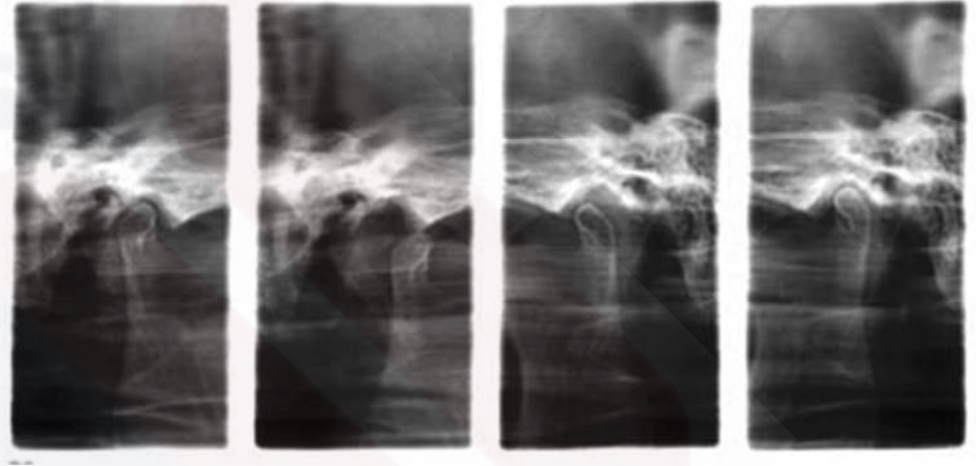
---



	Lateral Ceph	SMV	Waters	PA Ceph	Reverse Towne	Oblique Body	Lateral Ramus	Panoramic
Anterior mandible	■	■		■				□
Mandibular body	□	□		■		■		■
Ramus				■		□	■	■
Coronoid process			■	■	□		■	■
Condylar neck				■	■		■	■
Condylar head		■	□	□	■		■	□
Anterior maxilla	■		□	■				■
Posterior maxilla	□	■	□	□		□		■
Orbit	■	□	■	■				
Zygoma	□	□	■	□				■
Zygomatic arch		■	■					□
Nasal bones	■		■	□				
Nasal cavity	□	□	■	■	□			□
Maxillary sinus	■	□	■	□				■
Frontal sinus	■	□	■	■				
Ethmoid sinus	□	■	■	■				
Sphenoid sinus	■	■	□					




□ Low usefulness  
 ■ Medium usefulness  
 ■ High usefulness  
 No symbol: not recommended

This radiograph is more common for TMJ instead of TMJ projections



END

	Lateral Ceph	SMV	Waters	PA Ceph	Reverse Towne	Oblique Body	Lateral Ramus	Panoramic
Anterior mandible	Medium usefulness	Medium usefulness		Medium usefulness				Low usefulness
Mandibular body	Low usefulness	Low usefulness		Medium usefulness		High usefulness		High usefulness
Ramus				Medium usefulness		Low usefulness	High usefulness	High usefulness
Coronoid process			High usefulness	Medium usefulness	Low usefulness		High usefulness	Medium usefulness
Condylar neck				Medium usefulness	High usefulness		High usefulness	Medium usefulness
Condylar head		Medium usefulness	Low usefulness	Low usefulness	High usefulness		Medium usefulness	Low usefulness
Anterior maxilla	Medium usefulness		Low usefulness	Medium usefulness				Medium usefulness
Posterior maxilla	Low usefulness	Medium usefulness	Low usefulness	Low usefulness		Low usefulness		High usefulness
Orbit	Medium usefulness	Low usefulness	High usefulness	High usefulness				
Zygoma	Low usefulness	Low usefulness	High usefulness	Low usefulness				Medium usefulness
Zygomatic arch		High usefulness	Medium usefulness					Low usefulness
Nasal bones	High usefulness		Medium usefulness	Low usefulness				
Nasal cavity	Low usefulness	Low usefulness	Medium usefulness	High usefulness	Low usefulness			Low usefulness
Maxillary sinus	Medium usefulness	Low usefulness	High usefulness	Low usefulness				Medium usefulness
Frontal sinus	High usefulness	Low usefulness	Medium usefulness	High usefulness				
Ethmoid sinus	Low usefulness	Medium usefulness	Medium usefulness	Medium usefulness				
Sphenoid sinus	High usefulness	High usefulness	Low usefulness					

 Low usefulness  
 Medium usefulness  
 High usefulness  
 No symbol: not recommended